



**PRESENTING CLINICAL SIGNS**

**DATE** History: New murmur. Asymptomatic.

**ECHOCARDIOGRAPHIC FINDINGS**

11/18/21 2D, M-mode, and Doppler study.

**PERFORMED BY:**

Dr. Meredith Swart

There is mild left atrial dilation. The mitral valve leaflets are mildly thickened and exhibit mild systolic prolapse. There is Doppler evidence of mitral regurgitation present. There is mild left ventricular dilation. Left ventricular systolic function is normal. The aorta and aortic valve are normal. Right atrial and right ventricular dimensions are normal. The tricuspid is normal. The pulmonary artery and pulmonic are normal. No pericardial effusion or cardiac masses are seen.

**INTERPRETED BY**

Keith Blass, DVM,  
MS, DACVIM  
(Cardiology)

LA - 27.6 mm  
LVIDd - 27.2 mm  
LVIDs - 15.4 mm  
FS - 43.4%  
RA - 25.4 mm  
LVOT - 1.39 m/s  
RVOT - 0.86 m/s

**PATIENT**

Maci Kirby

**ASSESSMENT/RECOMMENDATIONS**

Degenerative mitral valve disease

**SPECIES**

Canine

This examination demonstrates regurgitation of blood across Maci's mitral valve resulting from degenerative valve disease. Secondary to her regurgitation, Maci has mild dilation of both her left atrium and left ventricle, though her left ventricular systolic function is well-preserved. As only mild left heart chamber dilation is present, Maci's mitral valve disease appears to be well-compensated, and her current risk for the development of clinical signs secondary to her disease, such as coughing, exercise intolerance, syncope, and labored breathing, appears to be relatively low.

**BREED**

Shih Tzu

I recommend starting Maci on pimobendan (2.5 mg am, 1.25 mg pm), as this medication should help to slow the progression of her mitral valve disease.

**SEX**

FS

A recheck echocardiogram is recommended in 9 months. Thoracic radiographs are recommended if Maci experiences respiratory clinical signs.

**AGE**

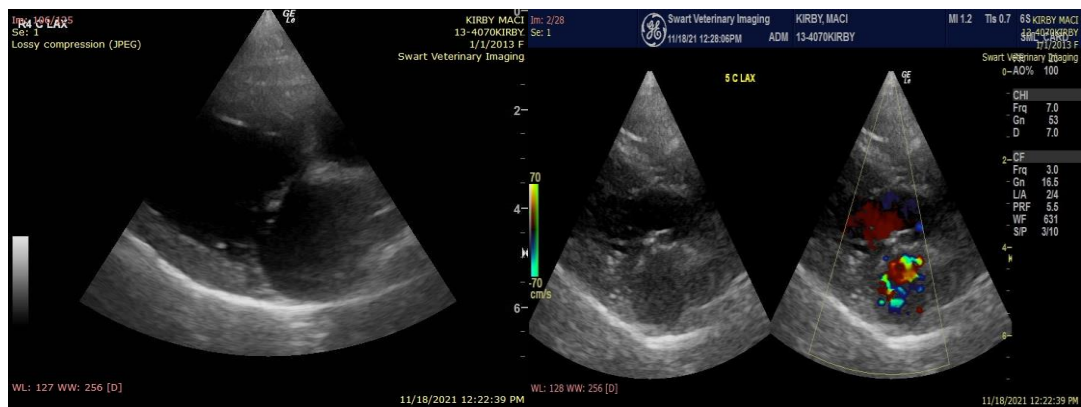
8 y

**WEIGHT**

14 lb

**HOSPITAL NAME**

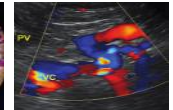
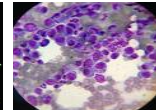
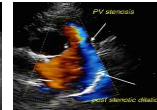
Swart Veterinary  
Imaging



**REFERRING VET**

Dr. Swart

The information and recommendations provided are based on the images presented by the



**DATE** referring veterinarian. No evaluation can be communicated regarding pathology that was not visible in the image/video clips provided.

11/18/21 Thank you for this referral. If the clinical or image interpretation does not parallel your findings or if I can be of any further assistance please contact me.

**PERFORMED BY:** Keith Blass, DVM, MS, DACVIM (Cardiology)  
KeithBlass@gmail.com  
Dr. Meredith Swart 631-804-5754

**INTERPRETED BY**

Keith Blass, DVM,  
MS, DACVIM  
(Cardiology)

**PATIENT**

Maci Kirby

**SPECIES**

Canine

**BREED**

Shih Tzu

**SEX**

FS

**AGE**

8 y

**WEIGHT**

14 lb

**HOSPITAL NAME**

Swart Veterinary  
Imaging

**REFERRING VET**

Dr. Swart